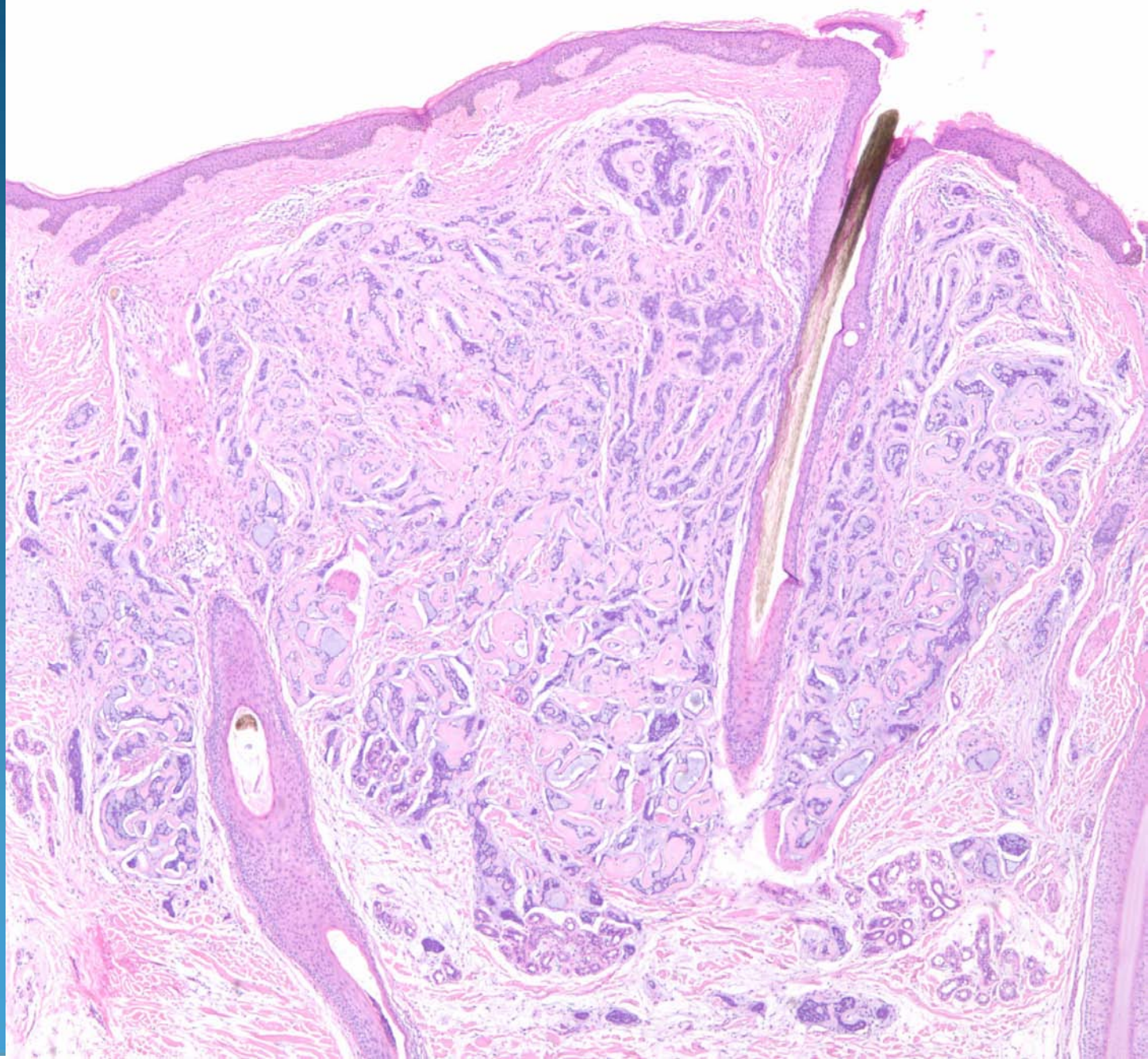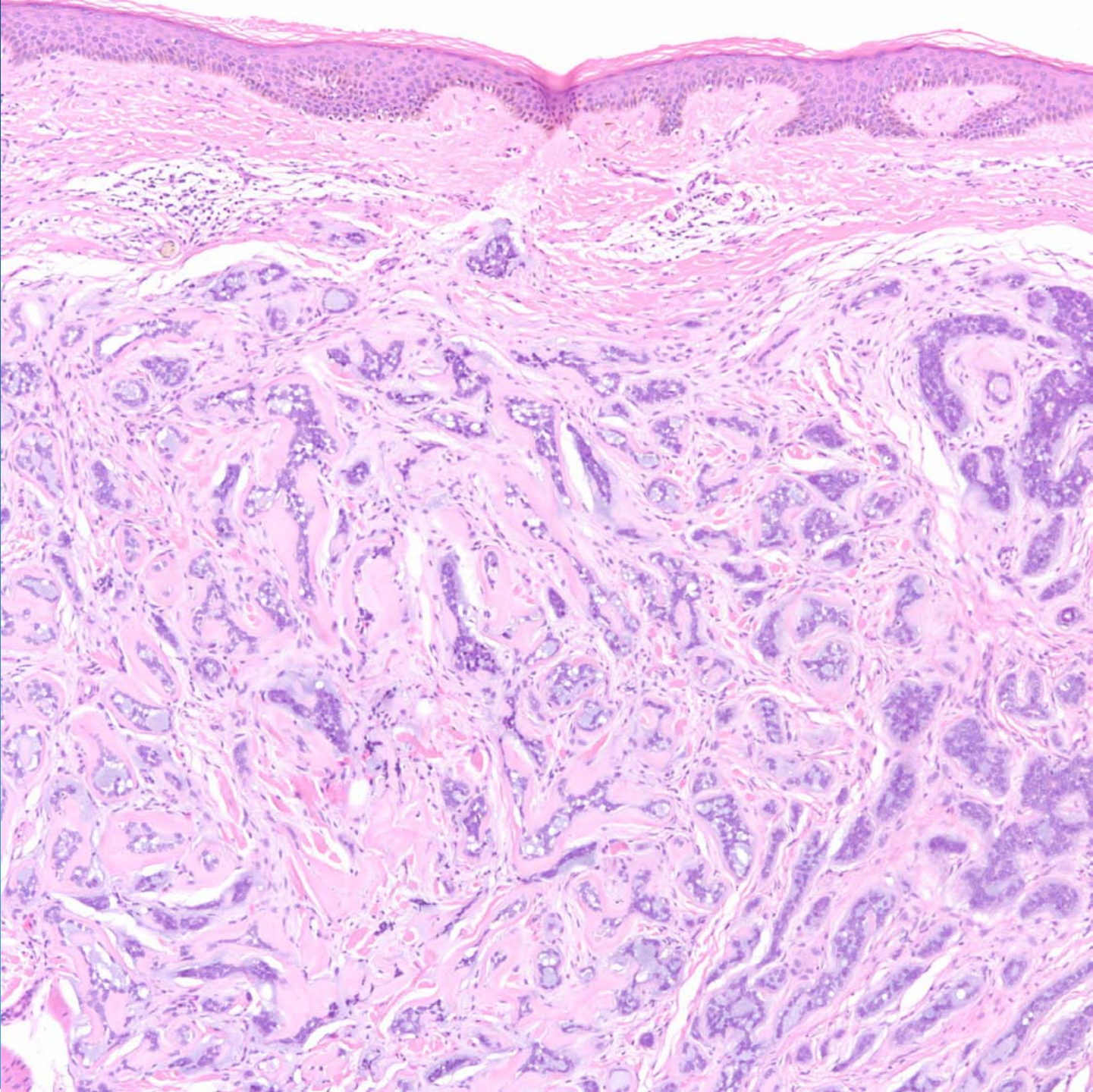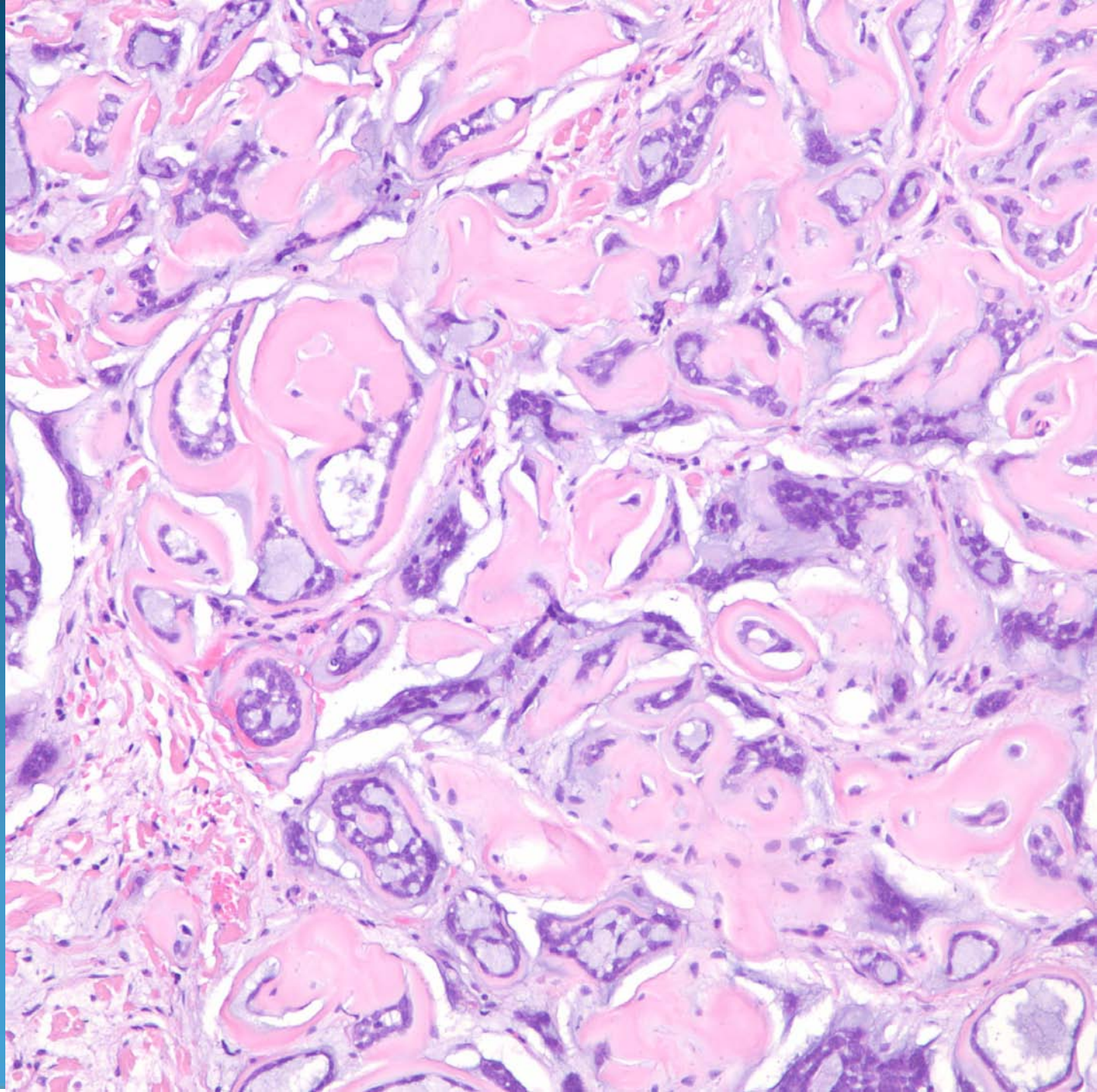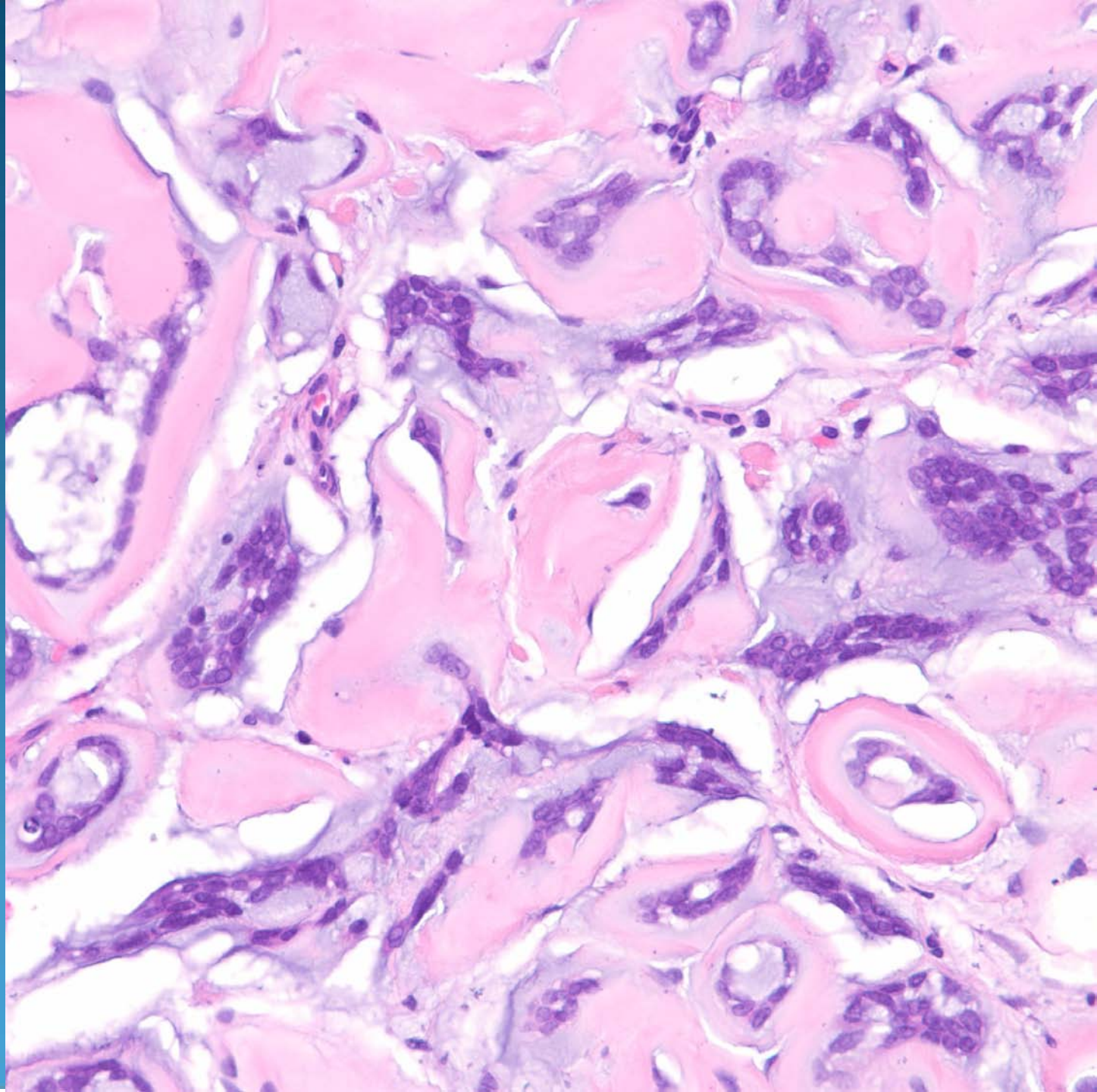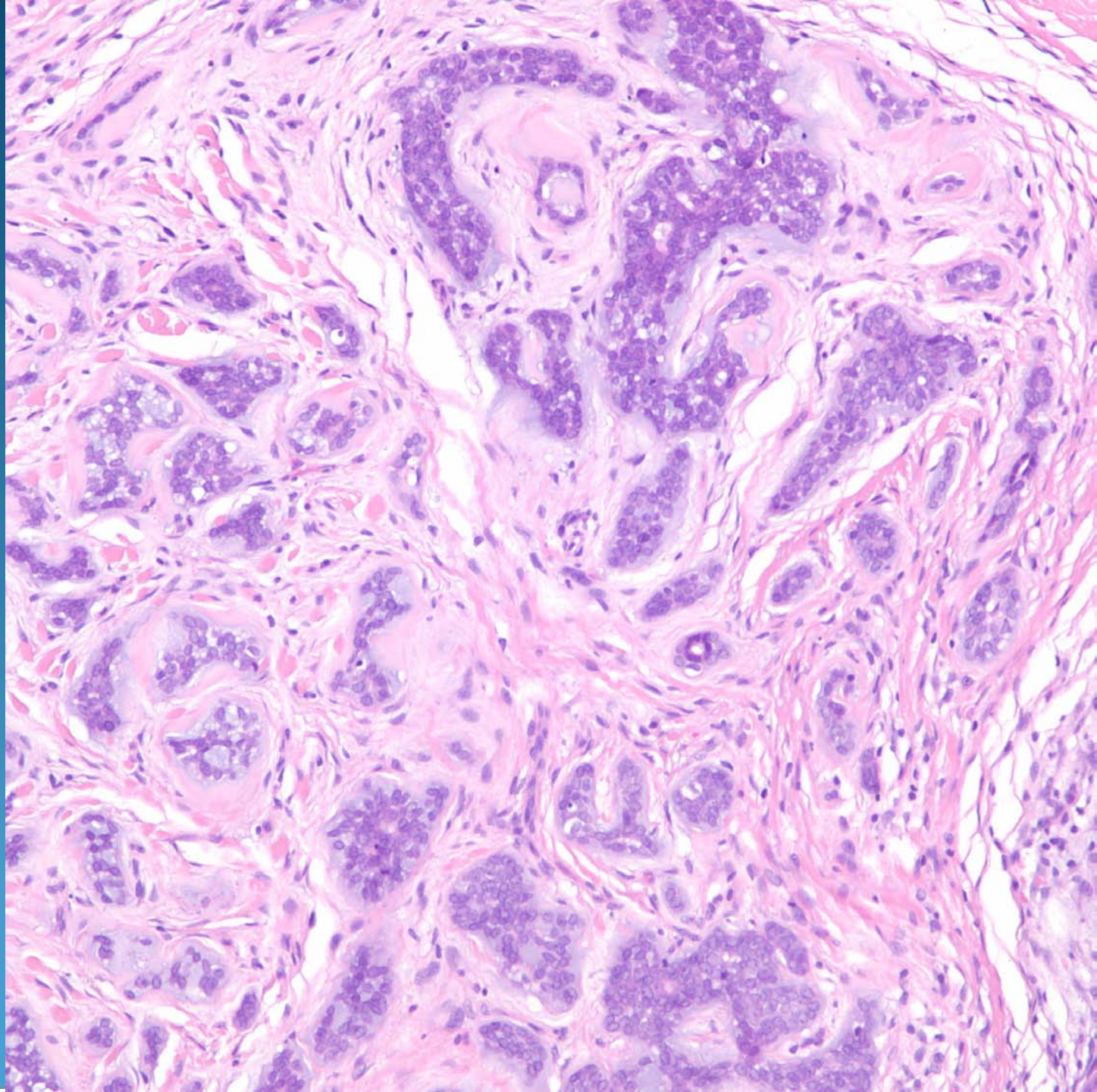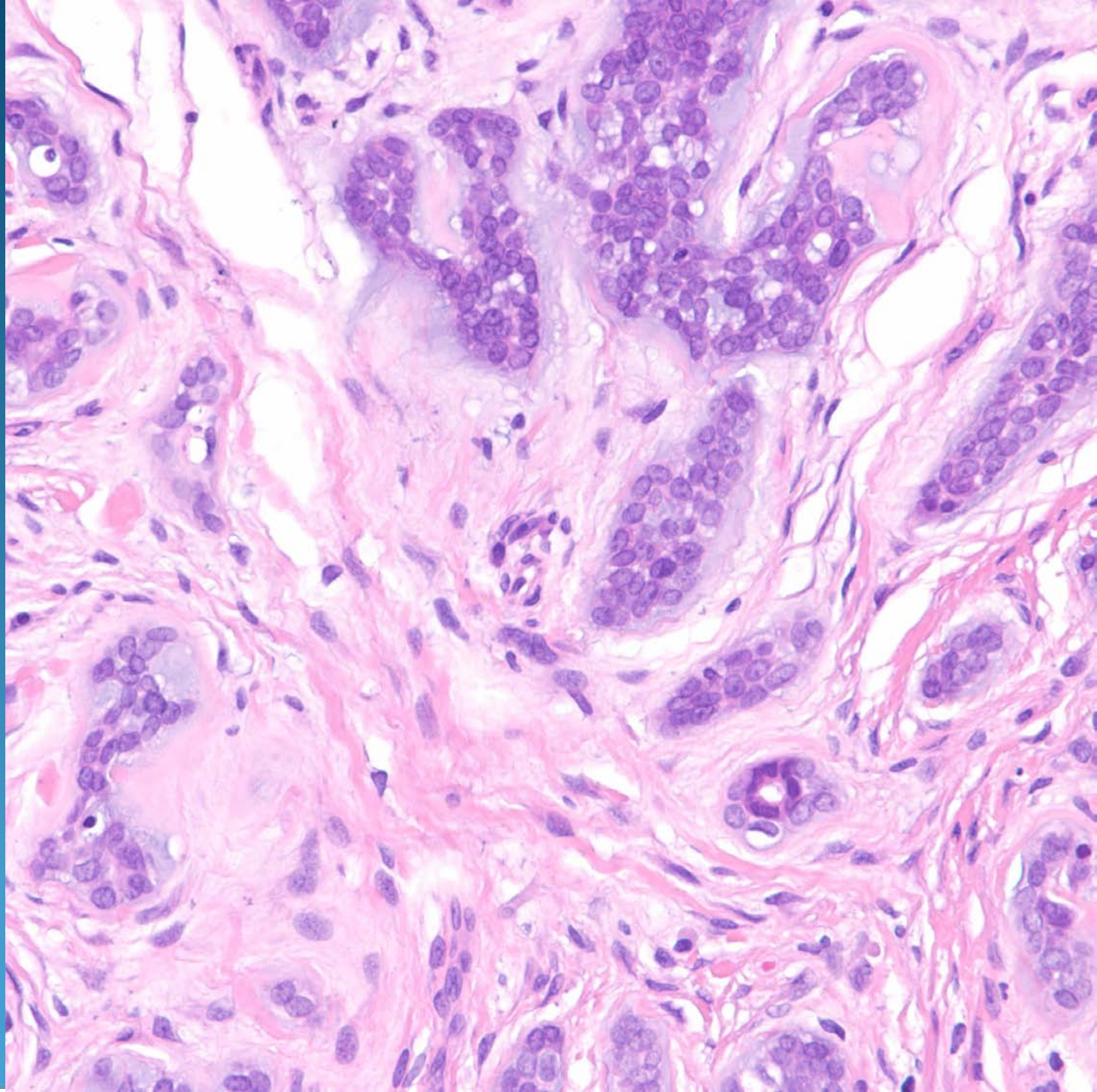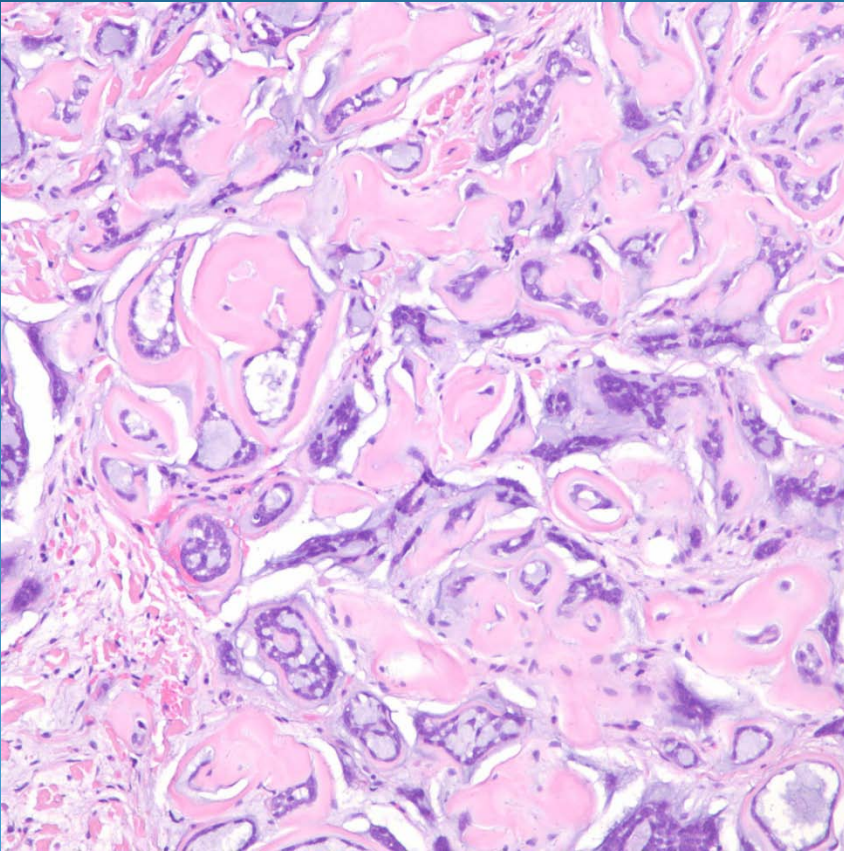


Adenoid Cystic Carcinoma of the Skin

Pearls



- Cellular blue tumor with “cookie cutter – like” architecture and hyalinized basement membranes
- Always rule out metastatic adenoid cystic carcinoma to the skin